

PATIENT

Trudy Lopez

SPECIES

Canine

BREED

Irish Setter

SEX

FS

AGE

10 years

WEIGHT

32kgs

INTERPRETED BY

Maggie Machen Lamy,
DVM, DACVIM
(Cardiology)

IMAGING PERFORMED BY

Loetitia Saint-Jacques,
LVT

HOSPITAL NAME

Roundhill Animal
Hospital

REFERRING VET

Dr. Kelly

INVOICE

46766

DATE

2/09/26

PRESENTING CLINICAL SIGNS

- History: Diagnosed with diabetes 1-27-26
- Presented on 2-4-26 for new symptoms, including reduced appetite, "collapsing" (rear end mobility is extremely poor). Suspect diabetes melitus.
- Episodes of extreme weakness. Almost like syncope but not quite. Also tachycardia is a concern. No heart murmur.

ELECTROCARDIOGRAPHIC FINDINGS

A six lead ECG is available at 25/50mm/s; 10mm/mV. The average heart rate is 170bpm (range 115-220bpm). The heart rate oscillates with frequent sinus tachycardia and an apparent warm up and cool down period (see att. photos). The rhythm is sinus in origin, with a p for every QRS complex and vice versa. The P wave morphology is positive with a normal dimension. Normal PR. The QRS morphology is positive with normal dimension. MEA is normal. No ectopic beats, pauses or dysrhythmias observed.

ECG diagnosis: Intermittent sinus tachycardia.

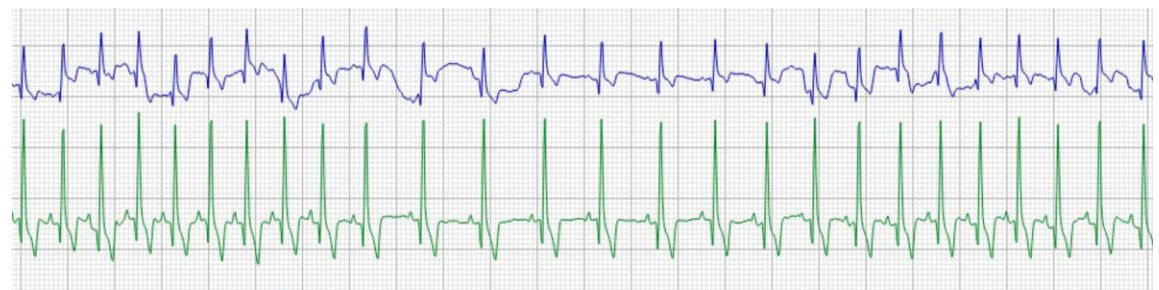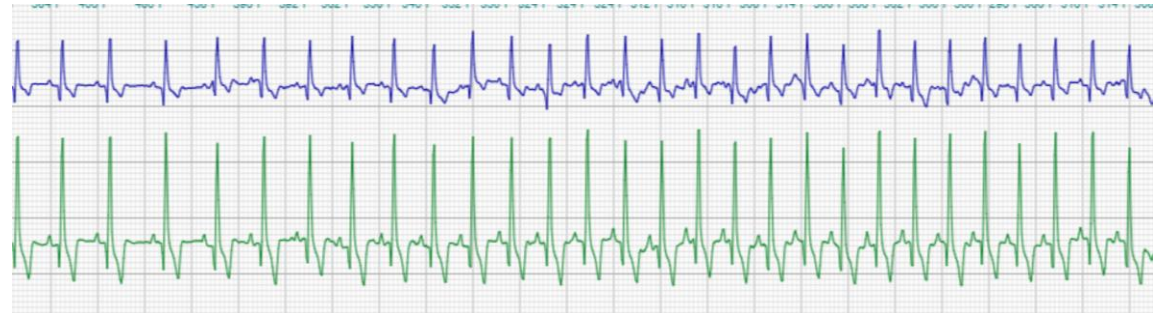INTERPRETATION OF THE FINDINGS & FURTHER RECOMMENDATIONS

The submitted ECG is most consistent with a sinus tachycardia, given a warm up and cool down period seen throughout. No dysrhythmias are observed.

It is assumed that the finding of a sinus tachycardia is secondary to the primary issue in this case, rather than being a cause of any clinical signs. Further systemic work up is advised. If suspicion persists, a holter could be considered.

No treatment is indicated based upon these findings.

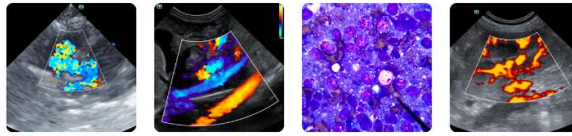
IMAGES



Imaging
performed by



Roundhill Animal Hospital Sonography, Inc.
pawsonography@gmail.com
530-786-8340



Clinical Sonography & Telectyology
Educational Teleconsultation Services™

SonoPath

FOSTERING THE ART OF VETERINARY MEDICINE™

SonoPath.com info@sonopath.com 1.800.838.4268

PATIENT

Trudy Lopez

SPECIES

Canine

BREED

Irish Setter

SEX

FS

AGE

10 years

WEIGHT

32kgs

INTERPRETED BY

Maggie Machen Lamy,
DVM, DACVIM
(Cardiology)

**IMAGING
PERFORMED BY**

Loetitia Saint-Jacques,
LVT

HOSPITAL NAME

Roundhill Animal
Hospital

REFERRING VET

Dr. Kelly

INVOICE

46766

DATE

2/09/26

The information and recommendations provided are based on the images presented by the referring veterinarian. No evaluation can be communicated regarding pathology that was not visible in the image/video clips provided.

Thank you for this referral. This report was generated using transcription software, and minor dictation errors may be present. If the clinical or image interpretation does not parallel your findings or if I can be of any further assistance, please contact me.

Maggie Machen Lamy, DVM
Diplomate of the American College of Veterinary Internal Medicine (Cardiology)
info@sonopath.com